

Role of MRI (magnetic resonance imaging) versus conventional imaging for breast cancer presurgical staging in young women or with dense breast

N. Biglia*, V.E. Bounous, L. Martincich, E. Panuccio, V. Liberale, L. Ottino, R. Ponzone, P. Sismondi

Oncological Gynaecology, Largo Turati 62, 10128 Torino, Italy

Accepted 9 December 2010
Available online 14 January 2011

Abstract

Aims: The role of magnetic resonance imaging (MRI) in the local staging of breast cancer is currently uncertain. The purpose of this prospective study is to evaluate the accuracy of preoperative MRI compared to conventional imaging in detecting breast cancer and the effect of preoperative MRI on the surgical treatment in a subgroup of women with dense breasts, young age, invasive lobular cancer (ILC) or multiple lesions.

Methods: Between January 2006 and October 2007, 91 patients with newly diagnosed breast cancer underwent preoperative clinical breast examination, mammography, bilateral breast ultrasonography and high-resolution breast MRI. All patients had histologically verified breast cancer. The imaging techniques were compared using the final pathological report as gold standard.

Results: The sensitivity of MRI for the main lesion was 98.9%, while for multiple lesions sensitivity was 90.7% and specificity 85.4%. After preoperative MRI, 13 patients (14.3%) underwent additional fine needle/core biopsies, 9 of whom had specimen positive for cancer. Preoperative MRI changed the surgical plan in 26 patients: in 19.8% of the cases breast conservative surgery was converted to mastectomy and in 7.7% of the patients a wider excision was performed. At a mean follow-up of 48 months, 2 local recurrences occurred (local failure rate = 2.5%).

Conclusions: Enhanced sensitivity of breast MRI may change the surgical approach, by increasing mastectomy rate or suggesting the need of wider local excision. MRI can play an important role in preoperative planning if used in selected patients with high risk of multifocal/multicentric lesions. However, the histologic confirmation of all suspicious findings detected by MRI is mandatory prior to definite surgery. © 2011 Published by Elsevier Ltd.

Keywords: Breast cancer; Magnetic resonance imaging; Breast conserving surgery; Surgical treatment; Mastectomy; Local recurrence rate

Introduction

Mammography (Mx), ultrasonography (US) and clinical examination are the conventional diagnostic techniques for the detection and local staging of breast cancer. Mx is the best screening modality in post-menopausal women, but its sensitivity is lower in young women, in women with a high genetic risk, or with dense breasts. Furthermore, conventional imaging and clinical examination frequently underestimate tumour size and multifocality.¹ This is especially evident in invasive lobular carcinoma (ILC), which accounts for 5–20% of breast carcinomas.²

Dynamic contrast-enhanced magnetic resonance imaging (MRI) is a complementary diagnostic modality in breast imaging, with reported sensitivities approaching 100% for invasive breast cancer^{3,4} and 40–100% for ductal carcinoma in situ (DCIS) respectively.¹ MRI identifies additional tumour foci in the ipsilateral breast^{5–8} that are not evident on physical examination, Mx, or US in 16% of patients and identifies mammographically occult contralateral breast cancers in 3% of women with a diagnosis of unilateral invasive breast cancer.⁹ As a consequence, potential benefits of preoperative MRI are a better selection of the patients suitable for breast conserving surgery (BCS)¹⁰ and a lower frequency of re-excision to obtain negative margins.¹¹ These benefits would provide a compelling rationale for the routine use of preoperative MRI in all cases of breast cancer, but, unfortunately, at present there are no

* Corresponding author. Tel.: +39 (0)11 5082684.
E-mail address: nicoletta.biglia@unito.it (N. Biglia).

data from prospective randomised trials showing evidence of improvement in patient outcome.¹²

In the case of BCS, one of the main parameters to assess treatment efficacy is the incidence of local recurrences.¹³ MRI does find additional foci of cancer, but the relevance of these findings is still uncertain: clinical evidence indicates that the majority of the foci identified only by MRI are likely controlled with breast irradiation⁷ as demonstrated by the low 5-year rate of local recurrence after BCS (4.3–10%).^{14,15} Furthermore, as shown by the results of the recent multicenter randomised COMICE trial, MRI added to conventional triple assessment, does not significantly reduce reoperation rates within 6 months (18.8% in the MRI group versus 19.3% in the non MRI group).¹⁶

In addition, MRI has a low specificity, ranging from 65 to 79%^{17,18} and it overestimates the extent of disease in 38.9% of cases,¹⁹ leading to a higher proportion of mastectomies.^{8,15,20}

The main goal of this study is to determine how the surgical management was modified based on the preoperative high-resolution breast MRI. The secondary aims of this study were the evaluation of the accuracy of preoperative MRI on breast cancer locoregional staging and the comparison of MRI with conventional imaging in a selected subgroup of patients with high mammary density or with lobular histotype or with suspected multifocal lesions.

Methods

Patients

Between January 2006 and October 2007, 91 sequential patients with newly diagnosed breast entered this prospective study.

The inclusion criteria were: age <45; age >45 with dense mammography breast pattern; invasive lobular cancer; suspected multifocal or multicentric disease at any age (Table 1). Patients with contraindication to MRI, those with a previous ipsilateral breast cancer or women requiring neoadjuvant chemotherapy were excluded from the study.

All patients underwent clinical breast examination, bilateral Mx, bilateral breast US. Surgical approach was first chosen for each case according to conventional imaging and clinical evaluation; afterwards, the treatment plan was redefined by the surgeons and radiologists on the basis

Table 1
Study population and inclusion criteria.

Characteristics of the study population	Median (range)
Age	44 [26–83]
BMI	23.1 [17.9–35.1]
Inclusion criteria	n %
Age < 45	38 41.8
ILC	12 13.2
Possibly multifocal	34 37.3
Dense mammographic pattern	7 7.7

of results of MRI and subsequent fine needle cytology/core biopsies of suspicious lesions. Surgical treatment was based on the extent of the disease, the number of tumour foci and the breast size (Fig. 1).

MRI technique

Breast MRI was performed by 1.5T equipment (Signa Excite HDx GE Healthcare, Milwaukee, Ill USA) and dedicated phased-array 8-channel coil with the patients in the prone position. After a localiser on the three orthogonal plane and coil calibration, morphologic study was obtained by T2-weighted images in the sagittal plane with the following parameters: TR 3700 ms, TE 68.0 ms, slice thickness 3.0 mm, interval 0.3 mm, FOV 22 × 22 cm, matrix 256 × 256, acquisition 3' 50"). Dynamic study was acquired with parallel imaging technique by a 3D fat-suppressed gradient echo sequence (VIBRANT, GE Healthcare, Milwaukee, Ill, USA) in the axial plane (TR 5.4 ms, TE 2.6 ms, TE in phase, flip angle 10°, slice thickness 2.6 mm, matrix 320 × 320 and acquisition time ranging between 45 and 60"). Dynamic sequences were acquired before and four times consecutively after intravenous administration by power injector of 0.1 mmol gadolinium-DTPA/kg body weight (Magnevist; Schering, Berlin, Germany) at a rate of 2 ml/s, followed by a saline flush of 20 mL at the same injection rate. A late sequence was performed 3 min after the last one.

MR images were post-processed at a workstation (Advantage 4.2, GE Healthcare, Milwaukee, Wis, USA) using

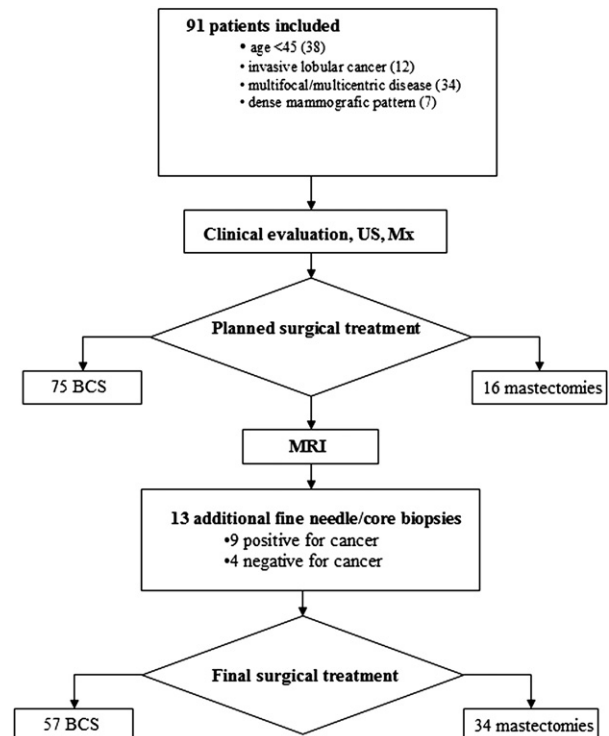


Figure 1. Study design.

image subtraction (contrast-enhanced minus unenhanced), multiplanar and maximum intensity projection (MIP) reconstruction algorithm and Time/Intensity Curve Analysis.

Breast MRI BIRADS lexicon²¹ was used to define the grade of suspicion for each mass and non mass enhancing lesions detected.

All suspicious MRI findings (BIRADS >3) were evaluated with ultrasound or mammographic second-look and verified by imaging-guided fine needle/core biopsy.

Surgical methods

BCS (lumpectomy, wide excision or quadrantectomy) was performed for single or multifocal lesions allowing a single excision. We defined as lumpectomy the surgical excision of a tumour with the removal of a minimal amount of surrounding tissue. For wide excision we referred to the surgical removal of an area of breast tissue containing the tumour, along with a rim of normal tissue around cancer. All surgical procedures were carried out with intraoperative frozen sections. Mastectomy was preferred in case of large or multicentric tumours.

Pathological evaluation

The surgical breast specimen were sectioned every 0.5 cm in parallel with the line between nipple and tumour. A detailed histopathologic study of the mastectomy or quadrantectomy specimen was carried out looking for additional cancer foci in the tumour-surrounding parenchyma. Accurate information on breast imaging was given to the pathologist in case of multifocal lesion.

Unifocal disease was defined as the presence of only one malignant focus in the breast; multifocal disease was defined as the presence of two or more malignant foci in the same quadrant as the index cancer; multicentric disease in case of one or more foci in a different quadrant to the index cancer.²²

In literature there is no consensus on the definition of free surgical margins. According to the National Surgical Adjuvant Breast and Bowel Project (NSABP), a negative margin is defined as tumour not touching ink.²³ Other authors consider as positive margin cancer cells within 1 mm, 5 mm or 10 mm from the ink.²⁴ In the present study, we defined as negative margin a distance from the inked surface >2 mm.

Statistical analysis

Statistical analysis was performed using SPSS for Windows. A significant correlation was defined as a $p < 0.05$ with a two tailed-test. The Kolmogorov–Smirnov method was used to define the normal distribution of variables. Sensitivity, specificity, positive predictive value and negative predictive value of all diagnostic techniques were calculated considering as gold standard the final pathological report. Comparison between imaging and pathological tumour

size measured on the index lesion was performed using paired *t*-test analysis, while the change in surgical strategy was evaluated with χ^2 analysis.

Results

Additional fine needle cytology/core biopsy after MRI

After preoperative MRI, 13 patients underwent additional fine needle cytology/core biopsy to characterise previously undiagnosed suspicious abnormalities prior to definitive surgery. Pathology was positive for cancer in 9 women. The planned surgical treatment was modified in 8 patients: in 6 cases BCS was converted to mastectomy and in 2 cases lumpectomy was changed into a wider excision. In 1 patient, additional contralateral lumpectomy was performed because of a contralateral DCIS detected only by MRI.

Pathological findings

The final pathological results for the 91 patients are shown in Table 2.

The mean diameter of the index lesion was 22 mm (SD \pm 14), ranging from 3 to 90 mm. Compared with final pathology results, US underestimated tumour size of 3.11 mm 95% CI [-7.08 \div 0.71] ($p = 0.108$), while Mx of 3.36 mm 95% CI [-7.49 \div 0.75] ($p = 0.108$). On the contrary, MRI overestimated tumour size of 3.1 mm 95% CI [0.54 \div 5.64] ($p = 0.018$).

Sensitivity and specificity in identifying the main lesion

In our study the sensitivity of Mx in identifying the index cancer was 84.6%, with 14 false negatives (FN), 2 of which were ILCs. US sensitivity was 80.2% (18 FN). Combining Mx and US we obtained a sensitivity of 100%. In our series MRI sensitivity was 98.9%; the only FN was a mixed lobular and ductal histotype bifocal cancer (5 and 6 mm) diagnosed both by Mx and US as a single lesion and not seen by MRI because of diffuse background enhancement.

Sensitivity and specificity in identifying multifocal and multicentric cancers

Postoperative surgical pathology demonstrated a single lesion in 50 patients, whereas 41 patients had multifocal or multicentric cancers (20 of which were bifocal).

Table 2
Histotype.

Histotype	n	%
IDC	66	72.5
ILC	12	13.2
Mixed IDC-ILC	3	1.4
DCIS	5	5.5
Other	5	5.5

In order to determine the accuracy in detecting multicentric or multifocal cancers, we compared the presence of multifocality/multicentricity identified through the different imaging techniques with the findings of pathological examination and our results are shown in Table 3. MRI was the most sensitive test in detecting multifocal/multicentric lesions, with 90.7% sensitivity versus 54.8% of conventional imaging combined.

Change in surgical management due to MRI

Depending on preoperative MRI, the surgical management changed in 26 patients. In 7 of them, scheduled to BCS, a wider excision was performed. In 1 patient, one additional contralateral lumpectomy for DCIS was done. In 18 patients BCS was changed to mastectomy: in 12 of them because of multifocality and in the remaining 6 because of the lesion size compared to breast size. MRI use was associated with a significant increase of the number of mastectomies performed (from 16 to 34; $p < 0.048$).

Breast outcome

In our series, after a mean follow-up of 48 months, 2 local recurrences occurred in 79 patients, with a local failure rate of 2.5%. For 12 women follow-up data are not available.

Discussion

Accuracy of MRI compared to conventional imaging

Mx and breast US have been widely used as primary imaging modalities for the diagnosis and local staging of breast cancer, but some studies have shown that MRI is superior to conventional imaging in the characterisation of the real extent of a breast tumour and in the identification of additional lesions and of DCIS, especially in women with dense breasts.¹

Mx tends to underestimate tumour size and multifocality; furthermore 5–15% of palpable breast cancers are not detected by Mx mostly due to high breast density. Mammographic sensitivity ranges from 100% in fatty breasts to 45% in extremely dense breasts.²⁵ US can help to characterise mammographically detected breast lesions

and measure tumour size, but has a limited value in detecting multifocal or bilateral breast cancer and DCIS.¹ In accordance with these data, in our series conventional imaging identified only 54.8% of multifocal/multicentric tumours.

In the study of Schelfout et al¹ diameters measured by MRI correlated best with histopathological size than diameters measured with Mx and US. In the study of Tse et al²⁶ Mx underestimated tumour size by 14% and US by 18%, whereas tumour size estimated by MRI did not significantly differ from final pathological measures. In our study MRI significantly overestimated the tumour diameter by about 3 mm.

In the literature, MRI sensitivity for invasive cancer ranges from 93% to 100%.¹⁸ In the present study high-resolution MRI showed a 98.9% sensitivity in detecting the main lesion and of 90.7% in identifying multicentric/multifocal lesions. MRI specificity for multiple lesions was 85.4%, while in the literature this value is generally lower, ranging from 30 to 80%.²⁰ In our series MRI showed a lower PPV (85%) for multifocal or multicentric lesions than conventional imaging (89%). In the literature, the average MRI PPV is 69%⁸ as MRI does not reliably discriminate benign from malignant findings. On the contrary MRI obtained a better NPV (91%) compared to conventional imaging (71%). In our series, FNs for multifocality are rare with MRI: if a lesion is identified as unifocal, there is a 91% probability that no other foci of breast tumour will be found at pathological examination.

MRI and multicentric/multifocal cancer

Studies on women with a diagnosis of unifocal breast cancer at physical examination and Mx, show that 30–63% have additional malignant foci in the ipsilateral breast at detailed histopathologic study of the mastectomy specimen.²⁷ Liberman et al²⁸ reported that MRI identified foci of cancers not seen by other modalities in 27% of women. A recent meta-analysis showed that MRI detects additional disease in the ipsilateral breast in 16% of women with breast cancer⁸ and identifies mammographically occult contralateral breast cancers in 3% of patients.⁹ In our study MRI detected additional lesions in 35.9% of patients. Probably this high detection rate is the result both of the selection criteria, which enriched the series with patients with a high likelihood of carrying multifocal/multicentric cancer, and of the high quality equipment used for MRI.

MRI and ILC

ILC frequently presents as a diffusely growing carcinoma and often fails to form distinct masses. As a consequence, Mx and US are associated with a high FN rate in patients with ILC.² Munot et al²⁹ reported a better sensitivity and a lower FP rate for MRI in comparison with conventional imaging for ILC detection. In our series, 12 patients

Table 3

Accuracy in detecting multifocality/multicentricity of the different imaging techniques.

%	Sensitivity	Specificity	PPV	NPV
US	44.2	91.2	83	65
MX	34.6	93.5	90	52
Standard Imaging (US + MX)	54.8	93.9	89	71
MRI	90.7	85.4	85	91

PPV: positive predictive value, NPV: negative predictive value; US: ultrasound, MX mammography, MRI magnetic resonance.

had ILC. In 2 of them Mx was falsely negative while MRI correctly identified all cases.

Change in surgical strategy

Conversion from WLE to more extensive conservative surgery or to mastectomy is the most common change in management resulting from preoperative MRI staging.³ A recent meta-analysis⁸ reported that in women with histology-proven additional foci of cancer detected by MRI, the conversion from WLE to mastectomy was 8.1% (95% CI, 5.9–11.3) and conversion from WLE to any more extensive surgery (wider/additional excision or mastectomy) was 11.3% (95% CI, 6.8–18.3). Many authors stress the importance to check any additional suspicious lesion identified through MRI with a second-look US or with fine needle cytology/core biopsy. Del Frate et al¹⁷ reported that, among 11% additional lesions identified by MRI, 61.5% were positive for cancer while 38.5% were benign lesions. In accordance with these findings, 14.3% of our patients underwent additional fine needle cytology/core biopsy because of a suspicious lesion identified by preoperative MRI: in 69.2% of them cytology/histology was positive for cancer.

In a prospective study,¹ preoperative MRI correctly changed the therapeutic approach in 30.6% of breast cancer patients; however, 7% of women underwent unnecessary wider excisions or extra fine needle cytology/core biopsies because of benign additional lesions or overestimation of tumour size on MRI. In our study, MRI changed surgical treatment in 28.5% of patients: the conversion rate from BCS to mastectomy was 19.8% and in 7.7% of the patients a more extensive conservative surgery was performed. When a mastectomy was performed based on the results of MRI, such clinical decision was always supported by the pathological final report. This is due to the fact that, as recommended by many authors, all MRI suspicious findings were verified by imaging-guided fine needle cytology/core biopsy prior to surgery.

MRI and breast cancer outcome

It is well established that MRI *changes* surgical management, usually from BCS to mastectomy; however, there is no evidence that it *improves* local control or prognosis.²² In the retrospective study by Solin et al,¹⁴ there were no differences in the 8-year rates of any local failure between women with or without preoperative breast MRI study (3% versus 4% respectively); as well as in overall survival rates (86% versus 87%, respectively). On the contrary, Fisher et al³⁰ observed a lower rate of local recurrences (1.2%) after conservative treatment in patients with a preoperative breast MRI compared to patients without a preoperative breast MRI (6.8%). In our series, the local recurrence rate was of 2.5% at a mean follow-up of 48 months.

The recent multicenter randomised COMICE trial has shown that routine breast MRI does not decrease reoperation

rates, but improves tumour localisation. Preoperative fine needle biopsy of MRI-only detected lesions minimises the incidence of inappropriate mastectomies.¹⁶

Conclusions

The clinical impact of preoperative MRI in surgical planning and prognosis of breast cancer patients is highly controversial. As confirmed in this study, MRI shows a great sensitivity in finding lesions not detectable with other techniques and improves the selection of patients for BCS. In particular, the use of a high-resolution equipment increases the detection rate. On the other hand, MRI leads to more mastectomies and to additional diagnostic biopsies, resulting in increased patient anxiety and costs.

Routine preoperative MRI for breast cancer staging means a too heavy burden on the patient without clear benefit, especially among women with fatty breast that can be easily investigated through conventional imaging. On the other hand, MRI can play an important role in preoperative planning if used selectively in young women or in patients with dense breast, provided that a strict histologic confirmation of any suspicious findings is warranted.

Further studies are needed to better evaluate if the changes in surgical management improve local disease control or prognosis.

Conflict of interest

We declare that this manuscript is original, it has not been published before and it is not currently being considered for publication elsewhere. We confirm that the manuscript has been read and approved by all named author. The corresponding author is the sole contact for the editorial process. He/she is responsible for communicating with the other authors about progress, submissions of revisions and final approval of proofs. We declare we have no actual or potential competing financial interest.

References

- Schelfout K, Van Goethem M, Kersschot E, et al. Contrast-enhanced MR imaging of breast lesions and effect on treatment. *Eur J Surg Oncol* 2004;**30**(5):501–7.
- Kepple MD, Layeeque R, Klimberg S, et al. Correlation of MRI and pathologic size of infiltrating lobular carcinoma of the breast. *Am J Surg* 2005;**190**:623–7.
- Hwang N, Schiller DE, Crystal P, et al. Magnetic resonance imaging in the planning of initial lumpectomy for invasive breast carcinoma: its effect on ipsilateral breast tumor recurrence after breast-conservation therapy. *Ann Surg Oncol* 2009;**16**(11):3000–9.
- Bluemke DA, Gatsonis CA, Chen MH, et al. Magnetic resonance imaging of the breast prior to biopsy. *JAMA* 2004;**292**:2735–42.
- Schnall MD, Blume J, Bluemke DA, et al. MRI detection of distinct incidental cancer in women with primary breast cancer studied in IBMC 6883. *J Surg Oncol* 2005;**92**:32–8.
- Hata T, Takahashi H, Watanabe K, et al. Magnetic resonance imaging for preoperative evaluation of breast cancer: a comparative study

- with mammography and ultrasonography. *J Am Coll Surg* 2004;**198**:190–7.
7. Morrow M, Freedman G. A clinical oncology perspective on the use of breast MR. *Magn Reson Imaging Clin N Am* 2006;**14**:363–78.
 8. Houssami N, Ciatto S, Macaskill P, et al. Accuracy and surgical impact of magnetic resonance imaging in breast cancer staging: systematic review and meta-analysis in detection of multifocal and multicentric cancer. *J Clin Oncol* 2008;**26**:3248–58.
 9. Lehman CD, Gatsonis C, Kuhl CK, et al. ACRIN Trial 6667 Investigators Group. MRI evaluation of the contralateral breast in women with recently diagnosed breast cancer. *N Engl J Med* 2007;**356**:1295–303.
 10. Pediconi F, Catalano C, Padula S, et al. Contrast-enhanced magnetic resonance mammography: does it affect surgical decision-making in patients with breast cancer? *Breast Cancer Res Treat* 2007;**106**:65–74.
 11. Wallace AM, Daniel BL, Jeffrey SS, et al. Rates of reexcision for breast cancer after magnetic resonance imaging-guided bracket wire localization. *J Am Coll Surg* 2005;**200**(4):527–37.
 12. Morrow M, Harris JR. More mastectomies: is this what patients really want? *J Clin Oncol* 2009;**27**(25):4038–40.
 13. Morrow M. Magnetic resonance imaging in the breast cancer patient: curb your enthusiasm. *J Clin Oncol* 2008;**26**(3):352–3.
 14. Solin J, Orel SG, Hwang WT, Harris EE, Schnall MD. Relationship of breast magnetic resonance imaging to outcome after breast-conservation treatment with radiation for women with early-stage invasive breast carcinoma or ductal carcinoma in situ. *J Clin Oncol* 2008;**26**(3):386–91.
 15. Bleicher RJ, Ciocca RM, Egleston BL, et al. The association of routine pre-treatment magnetic resonance imaging with time to surgery, mastectomy rate, and margin status. *J Am Coll Surg* 2009;**209**(2):180–7.
 16. Turnbull L, Brown S, Harvey I, et al. Comparative effectiveness of MRI in breast cancer (COMICE) trial: a randomised controlled trial. *Lancet* 2010;**375**:563–71.
 17. Del Frate L, Borghese L, Cedolini C, et al. Role of pre-surgical breast MRI in the management of invasive breast carcinoma. *Breast* 2007;**16**:469–81.
 18. Bilimoria KY, Cambic A, Hansen NM, Bethke KP. Evaluating the impact of preoperative breast magnetic resonance imaging on the surgical management of newly diagnosed breast cancers. *Arch Surg* 2007;**142**:441–7.
 19. Morrow M. Magnetic resonance imaging in the preoperative evaluation of breast cancer: primum non nocere. *J Am Coll Surg* 2004;**198**:240–1.
 20. Katipamula R, Hoskin TL, Boughey JC, et al. Trends in mastectomy rates at the Mayo Clinic, Rochester: effect of surgical year and preoperative magnetic resonance imaging. *J Clin Oncol* 2009;**27**(25):4082–8.
 21. www.acr.org.
 22. Houssami N, Hayes DF. Review of preoperative Magnetic Resonance Imaging (MRI) in breast cancer: Should MRI be performed on all women with newly diagnosed, early stage breast cancer? *CA Cancer J Clin* 2009;**59**(5):290–302.
 23. Fisher B, Anderson S, Bryant J, et al. Twenty-year follow-up of a randomized trial comparing total mastectomy, lumpectomy, and lumpectomy plus irradiation for the treatment of invasive breast cancer. *N Engl J Med* 2002;**347**(16):1233–41.
 24. Luini A, Rososchansky J, Gatti G, et al. The surgical margin status after breast-conserving surgery: discussion of an open issue. *Breast Cancer Res Treat* 2009;**113**:397–402.
 25. Berg WA, Gutierrez L, NessAiver MS, et al. Diagnostic accuracy of mammography, clinical examination, US and MR imaging in preoperative assessment of breast cancer. *Radiology* 2004;**233**(3):830–49.
 26. Tse GMK, Chaiwun B, Wong KT, et al. Magnetic resonance imaging of breast lesions—a pathologic correlation. *Breast Cancer Res Treat* 2007;**103**:1–10.
 27. Yabuuchi H, Kuroiwa T, Kusumoto C, Fukuya T, Ohno S, Hachitanda Y. Incidentally detected lesions on contrast-enhanced MR imaging in candidates for breast-conserving therapy: correlation between MR findings and histological diagnosis. *J Magn Reson Imaging* 2006;**23**:486–92.
 28. Liberman L, Morris EA, Dershaw DD, Abramson AF, Tan LK. MR imaging of the ipsilateral breast in women with percutaneously proven breast cancer. *Am J Roentgenol* 2003;**180**:901–10.
 29. Munot K, Dall B, Achuthan R, Parkin G, Lane S, Horgan K. Role of magnetic resonance imaging in the diagnosis and single-stage surgical resection of invasive lobular carcinoma of the breast. *Br J Surg* 2002;**89**(10):1296–301.
 30. Fischer U, Zachariae O, Baum F, von Heyden D, Funke M, Liersch T. The influence of preoperative MRI of the breasts on recurrence rate in patients with breast cancer. *Eur Radiol* 2004;**14**:1725–31.